

## Immunoglobulin deposits in Erythema Nodosum Leprosum (ENL)

JOSEPHINE ANTHONY(\*)  
M. C. VAIDYA (\*\*)  
A. DASGUPTA (\*\*\*)

**SUMMARY** — Erythema Nodosum Leprosum (ENL) skin lesions observed by fluorescence microscopy were found to contain immune complexes. While biopsies taken from at least seven ENL lesions contained deposits of immunoglobulin in their vessel walls, twelve of the lesions contained such deposits in the perivascular cell infiltrate. However, immunoglobulin deposits were observed in the dermis of all 25 ENL lesions studied. On the basis of localization of these fluorescent deposits the 25 skin lesions were classified under groups I to III and were correlated with the onset of the reaction. Control biopsies taken from the lepromatous leprosy patients without ENL were uniformly negative for immunoglobulin deposits.

*Key words:* Hanseniasis. ENL reaction. Immunology. Immunofluorescence.

### INTRODUCTION

One of the commonest episodes which punctuates the course of leprosy is Erythema Nodosum Leprosum (ENL). ENL occurs only in lepromatous and a small proportion of borderline patients. It is particularly common in treated lepromatous leprosy patients and about 50% of such patients in South-East Asia develop ENL by the end of the first year of treatment (11). Histologically the lesions are characterized by an intense polymorphonuclear leucocyte infiltration, vascular involvement and fi-

brinoid necrosis. This histological picture closely resembles the Arthus phenomenon in laboratory animals, which is known to be due to the deposition of immune complexes in blood vessel walls (2). The aim of this study is therefore to show that ENL is an immune complex disease wherein deposition of antigen-antibody complexes may constitute a characteristic feature of the disease.

### MATERIALS AND METHODS

Skin biopsies were taken from 25 lepromatous leprosy patients with ENL. All pa-

(\*) Senior Research Fellow, Cellular Immunology Laboratory, Department of Anatomy All-India Institute of Medical Sciences, New Delhi-110016, India.

(\*\*) Associate Professor, Cellular Immunology Laboratory, Department of Anatomy, All-India Institute of Medical Sciences, New Delhi-110016, India.

(\*\*\*) Assistant Professor, Immunology Division, Department of Microbiology, All-India Institute of Medical Sciences, New Delhi-110016, India.

## Immunoglobulin deposits in ENL

tients had active ENL lesions at the time of biopsy. Skin biopsies taken from 10 lepromatous leprosy patients without ENL served as controls. The tissue specimens were immediately placed in cold 95% ethanol and processed according to the method of Sainte-Marie (8).

At the time of biopsy, serum was collected from all patients for immunoglobulin and complement assay. *Reagents:* Human IgG was purified from normal pooled sera as described by Fahey & Terry (3). Rabbit antihuman immunoglobulin was prepared by the method described by Wemambu *et al.* (13). Di-ethylaminoethyl cellulose (DEAF) purified rabbit anti-human IgG with a high antibody titre was labelled with fluorescein isothiocyanate (5) and purified on Sephadex G-25' (4). Fractions containing not more than 2-3 molecules of fluorescein per protein molecule were pooled and stored at -70°C.

### IMMUNOFLUORESCENCE TEST

Sections of skin 5-7 thickness were cut and mounted on albumin-coated slides. Sections were deparaffinized in two consecutive changes of cold xylene for 10-15 seconds each and washed in three consecutive baths of cold ethanol for 10-15 seconds each to remove xylene. Slides were then rinsed in three changes of cold phosphate staining buffer pH 7 for one minute and

incubated at 37°C with FITC conjugated rabbit anti-human IgG for 30 minutes. They were then washed in phosphate staining buffer six times for 15 minutes each. Sections were mounted in a medium containing 9 parts of glycerol to 1 part of phosphate staining buffer and observed under Carl-Zeiss ultraphot II using mercury lamp HBO 200.

Parallel sections of skin were stained with Haematoxylin-Eosin and Ziehl-Neelsen stains.

### OBSERVATIONS

Immunoglobulin deposits were demonstrated in the dermis of 25 ENL skin lesions studied. No granular deposits were found in the 10 lepromatous leprosy patients without ENL. Depending on the distribution of these deposits the 25 ENL lesions studied were classified under Groups I, II, and III. Details of these are shown in Table 1.

In Group I, which consisted of 7 out of 25 ENL lesions, apple green fluorescent deposits were observed in and around the blood vessels (Fig. 1); few of the perivascular infiltrating cells (Fig. 2) and along the collagen and elastic fibres in the dermis. In Group II, consisting of 5 out of 25 ENL lesions, fluorescent deposits were distributed only in the perivascular infiltrating cells and in the dermis (Fig. 3).

TABLE 1

Detection of human IgG by immunofluorescence in the skin of lepromatous patients with ENL

Groups/ N.º of cases	N.º of days after onset of ENL	Non-specific fluorescence	Specific fluorescence		
			Blood vessels	Cell infiltration	Dermis
I/7	1 - 4	+	+	+	+
II/5	4 - 5	+	—	+	+
III/13	5 - 10	+	—	—	+

In Group III, consisting of 13 out of the 25 ENL lesions, fluorescent deposits were observed only in the dermis (Fig 4). In all lesions which were positive for the immunofluorescent test, granular deposits

of IgG in the dermis were irregularly arranged and did not appear in a linear manner. Fluorescent granular deposits could also be demonstrated in the sweat glands of all skin lesions.

TABLE 1

Detection of human IgG by immunofluorescence in the skin of lepromatous patients with ENL

Groups/ N. <sup>o</sup> of cases	N. <sup>o</sup> of days after onset of ENL	Non-specific fluorescence	Specific fluorescence		
			Blood vessels	Cell infiltration	Dermis
I/7	1 - 4	+	+	+	+
II/5	4 - 5	+	—	+	+
III/13	5 - 10	+	—	—	+

While high levels of immunoglobulin (IgG) were observed in both LL and ENL patients, serum complement (C3) levels were decreased in 22/25 ENL patients and elevated in 8 out of 10 LL patients without ENL (Table 2).

#### DISCUSSION

The immunofluorescence findings in the lesions were quite distinctive and consisted of bright, green and granular pattern of staining of IgG along the basement membrane of vessels, around blood vessels, cell infiltration and in the dermis. In contrast skin lesions from LL patients which formed the controls failed to produce any such localization of specific fluorescence in these sites. However, pale diffuse nonspecific fluorescence of collagen fibres and fluorescent deposits in sweat glands were recognised in the skin lesions of ENL as well as LL patients. These results thus confirm and extend the findings of Wemambu *et al.* (13) and Waters *et al.* (12) who described the presence of granular deposits of immunoglobulin and complement in perivascular distribution corresponding with areas of polymorphonuclear infiltration in ENL lesions. However, the observations in the present study of the presence of granular deposits in the sweat glands of all skin lesions is probably due to the non-specific fluorescence of lipid bodies present in the secretory coil of these glands. These lipid bodies are intensely autofluorescent in U. V. light (9).

Depending on the localisation of the fluorescent deposits of IgG, ENL lesions

in the present study have been classified under three groups. In group I, granular fluorescent deposits are seen in the basement membrane of the blood vessels where they get deposited and trapped which is probably the earliest detectable point of antigen-antibody deposition. In group II, granular deposits are observed in the cellular infiltrate of the dermis rather than in the blood vessels. The position and type of the cells exhibiting fluorescence was ascertained by comparing the relationship of the fluorescence with the corresponding section stained with routine haematoxylin-eosin. The fluorescence was generally seen in cell aggregates which consisted of polymorphonuclear leucocytes and macrophages. The finding of variable amounts of fluorescence of a sharp nature present in some but not all of these cells verifies against nonspecific leucocyte fluorescence. Moreover, these deposits in the dermis did not correspond to areas of bacillary infiltration. In group III disappearance of IgG deposits occurred from blood vessels and infiltration of cell, though few irregularly arranged granular deposits were seen in the connective tissue of the dermis. The presence of IgG deposits in the dermis of all the 25 ENL biopsies can be explained on the basis that all lesions were tender and painful at the time of biopsy. A similar view has been expressed by Waters *et al.* (12) who suggested that ENL lesions already changing colour and beginning to subside are often negative for IgG and complement fluorescence.

The concept that ENL is mediated by an antigen-antibody reaction gains further support by the finding of low levels of com-

*Immunoglobulin deposits in ENL*

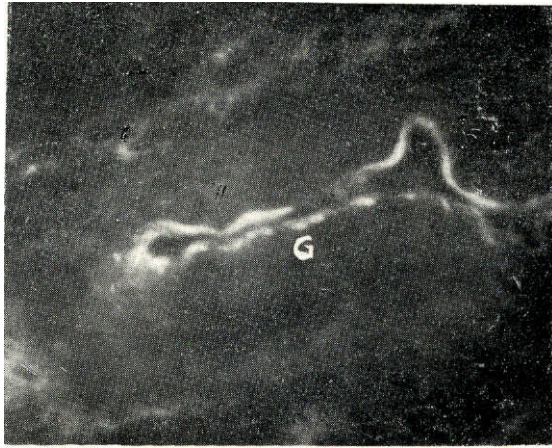


Fig. 1 — Fluorescence micrograph of a section of ENL skin showing granular fluorescent deposits of IgG (G) along the vascular basement membrane. x 525.

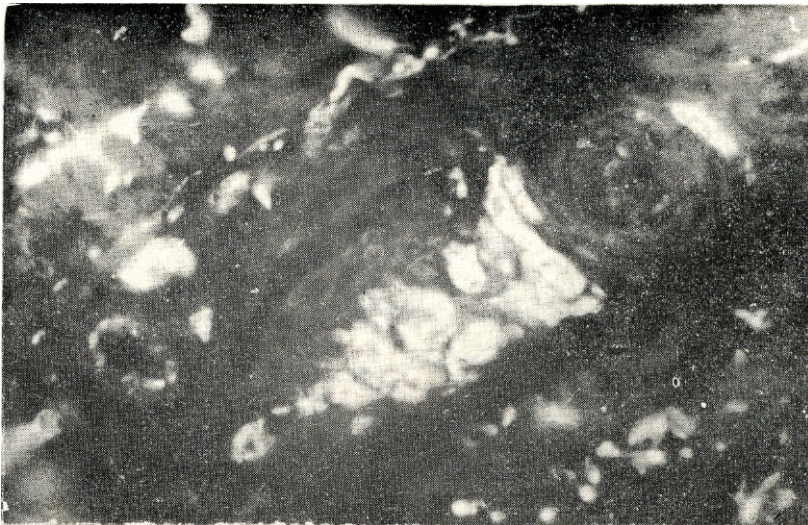


Fig. 2 — Fluorescence micrograph of a section of ENL skin showing localisation of granular deposits in the basement membrane of a blood vessel and in cells in the dermis. x 490.

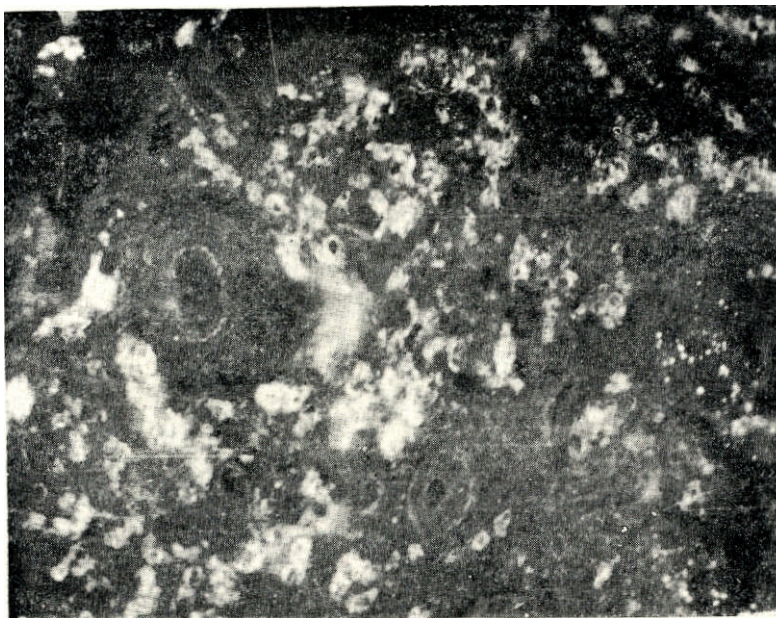


Fig. 3 — Fluorescence micrograph of a section of ENL skin. Note the fluorescing peri-vascular cell infiltrate. x 300.

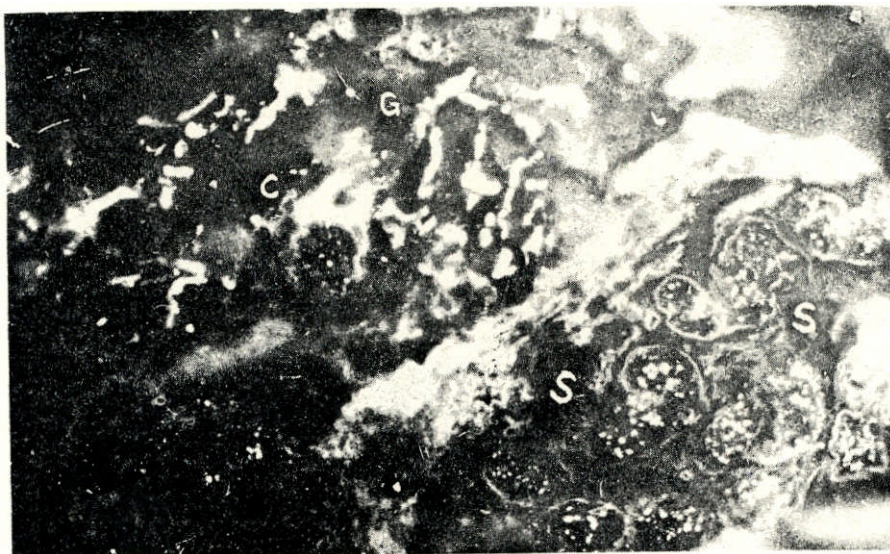


Fig. 4 — Fluorescence micrograph showing granular deposits of IgG (G) in the dermis of ENL skin. Nonspecific autofluorescence of collagen fibres (C) and sweat glands (S) are also observed. x 160.

plement, and this finding is confirmed with the observation of other workers (1, 7, 10). Similar decrease in serum complement levels have also been described in other immune complex disease such as acute glo-

merulonephritis and acute lupus erythematosus (6). It would thus appear that depressed serum complement levels in ENL may be due to its being utilised during the course of the antigen-antibody reaction.

#### ACKNOWLEDGEMENTS

The authors wish to thank Dr. E. S. Short, Bethesda Leprosy Mission Hospital, Narsapur, A. Pradesh, India; for the ENL and LL skin biopsies.

#### REFERENCES

1. AZEVEDO, M. P. & MELO, P. H. A comparative study of the complementary activity of serum in the polar forms of leprosy and in the leprosy reaction. *Int. J. Lepr.*, 34(1):34-38, 1966.
2. COCHRANE, C. G. & WARD, P. A. The role of complement in lesions induced by immunologic reactions. In: INTERNATIONAL SYMPOSIUM ON IMMUNOPATHOLOGY, 4th, 1966. New York, Grime & Stratton, 1966. p. 433-445.
3. FAHEY, J. L. & TERRY, E. W. Ion exchange chromatography and gel filtration.. In: WEIR, D. M., ed. *Handbook of experimental immunology*. Oxford, Blackwell Scientific Publications, 1967. p. 19-43.
4. FOTHERGILL, J. E. Fluorochromes and their conjugation with proteins. In: NAIRN, R. C., ed. *Fluorescent protein tracing*. London, Livingstone, 1964. p. 25-33.
5. HOLBOROW, E. J. & JOHNSON, G. D. Immunofluorescence. In: WEIR, D. M., ed. *Handbook of experimental immunology*. Oxford, Blackwell Scientific Publications, 1967. p. 571-597.
6. LANGE, K.; WASSERMAN, E.; SLOBODY, L. B. The significance of serum complement levels for the diagnosis and prognosis of acute and subacute glomerulonephritis and lupus erythematosus disseminatus. *Ann. Intern. Med.*, 53(4):636-646, 1960.
7. MENEGHINI C-TRIMIGLIOZZI, G.; LOSPA LLUTI M-ANGELINI, G.; BONIFAZI, E. Immunological and haematological research in leprosy. In: WORLD CONGRESS OF THE INTERNATIONAL SOCIETY IN TROPICAL DERMATOLOGY. *Abstracts*. Japan, Kyoto, 1969. p. 29.
8. SAINTE-MARIE, G. A paraffin embedding technique for studies employing immunofluorescence. *J. Histochem. Cytochem.*, 10(3):250-256, 1962.
9. SPICER, S. S. & PRIOLEAU JR., W. H. Cytochemical studies of lipid and acid phosphatase in human eccrine sweat gland. *Lab. Invest.*, 27(1):9-16, 1972.
10. TIN SHWE. Serum complement (C3) in leprosy. *Lepr. Rev.*, 42(4):268-272, 1971.
11. WATERS, M. F. R.; REES, R. J. W.; SUTHERLAND, I. Chemotherapeutic trials in leprosy. 5. A study of methods used in clinical trials in lepromatous leprosy. *Int. J. Lepr.*, 35(3): 311-335, 1967.
12. WATERS, M. F. R.; TURK, J. L.; WEMAMBU, S. N. C. Mechanisms of reactions in leprosy. *Int. J. Lepr.*, 39:417-428, 1971.
13. WEMAMBU, S. N. C.; TURK, J. L.; WATERS, M. F. R.; REES, R. J. W. Erythema nodosum leprosum: a clinical manifestation of the Arthus phenomenon. *Lancet*, 2:933-935, 1969.

---

Received for publication February 1978.